

CASE REPORT

Leiomyoma of the upper extremity: A very rare presentation and review of literature

Rajesh K. Abbey, Karan Mittal, Kirti Goyal, Sahil Kalia

Department of Surgery, Maharishi Markandeshwar Institute of Medical Sciences and Research, Ambala, Haryana, India

Corresponding Author:

Dr. Rajesh K. Abbey, Department of Surgery, Maharishi Markandeshwar Institute of Medical Sciences and Research, Ambala, Haryana, India. Phone: +91-9418095677. E-mail: abbisml@gmail.com

Received: 04-04-2019

Accepted: 14-04-2019

How to cite this article:

Abbey RK, Mittal K, Goyal K, Kalia S. Leiomyoma of the upper extremity: A very rare presentation and review of literature. Int J Adv Integ Med Sci 2019;4(1):18-21.

Source of Support: Nil,

Conflicts of Interest: None declared.

INTRODUCTION

Leiomyomas are benign soft-tissue tumors arising from smooth muscles. The incidence is 4.4% of all benign soft-tissue tumors.^[1] Preponderance is seen in the 3rd–6th decades of life. Uterine leiomyomas are commonest in females, but are very rare in extremities, more so in upper extremities.^[2,3] These lesions have been accepted as rare neoplasms as very few cases have been described in the English literature.^[4] Some amount of striated muscles are present in tissues of extremities, such as arrector pili, walls of vessels and sweat glands, and leiomyoma arises from there.^[5] Leiomyomas arising in extremities are usually


Leiomyomas of the extremities are very rare and more so deep leiomyomas of the upper limbs. The literature mentions very few cases of deep soft-tissue leiomyomas of the upper limb. Leiomyomas represent 4.4% of all benign soft-tissue tumors. These are mainly of four types: Cutaneous, vascular, and those arising from deep soft-tissues. A case of soft-tissue leiomyoma of the forearm eroding midshaft of ulna is presented here and its radiological and histopathological correlations are discussed. A young female presented with a soft-tissue swelling of 1 year duration on the right forearm which turned out to be leiomyoma. The case is being presented for its extreme rarity and probability of misdiagnosing such tumors.

KEY WORDS: Immunohistochemistry, leiomyoma, soft-tissue tumor, wide excision

misdiagnosed. Leiomyomas, as tumors arising from smooth muscles, are not normally known to arise from extremities due to the paucity of smooth muscles in extremities. The clinical features cannot confirm leiomyoma though the radiological and histopathological investigations are helpful in the diagnosis and management of these tumors. The treatment comprises complete surgical excision and final diagnosis can be made based on histopathology and immunohistochemistry (IHC). One such case of deep leiomyoma of the right mid forearm is discussed here for its extreme rarity. The diagnostic modalities and treatment plan are also discussed.

CASE REPORT

A 32-year-old healthy female patient presented in surgery outpatient department with a firm, oval mass on the extensor surface of the right mid forearm, which was present for the past 1 year. The mass was slowly growing in size and was occasionally painful. On examination, it was a firm, oval swelling at the extensor aspect of the middle of the right forearm, overlying the

Access this article online	
Website: www.ijaims.net	Quick Response code
	

This is an Open Access article distributed under the terms of the Creative Commons Attribution 4.0 International License (<http://creativecommons.org/licenses/by/4.0/>), allowing third parties to copy and redistribute the material in any medium or format and to remix, transform, and build upon the material for any purpose, even commercially, provided the original work is properly cited and states its license.

ulna, situated in the deeper muscle planes. The swelling was not mobile in either direction and was non-tender. Overlying skin was normal. There were no fluctuations and transillumination could not be ascertained, as swelling was deep seated. There was no neurological or muscular deficit in the corresponding arm, hand, and fingers. There were no signs of abscess or inflammation and axillary lymph nodes were absent. There was no other swelling over the body of the patient. Radiology of the swelling revealed soft-tissue mass of the size of 8 cm × 5 cm × 2.5 cm on the right forearm. Plain X-ray in frontal and lateral views showed well-marked soft-tissue shadows causing multiple, small erosions of the shaft of the ulna underlying the mass [Figure 1]. Magnetic resonance imaging demonstrated well-defined soft-tissue density lesion involving intermuscular compartments of the right forearm at the dorsal aspect of ulna. No calcification or hemorrhage was noted within the lesion. The lesion was hyperintense on T1-weighted (T1W) images [Figure 2] and remained unsuppressed on T1W fat-suppressed images. The lesion was hyperintense to the adjacent muscles also on T2-weighted images and was displacing the extensor muscles of forearm posteriorly. Cortical irregularity of ulna with no intermedullary extension was noted. There were erosions

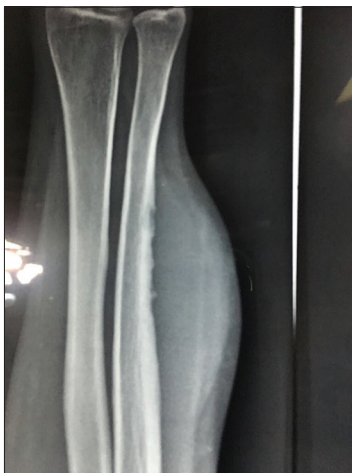

Figure 1: X-ray showing small multiple erosions of the ulnar shaft

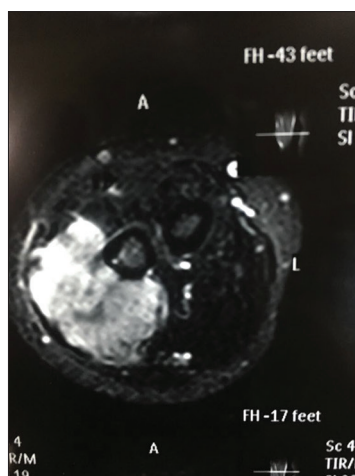


Figure 2: The magnetic resonance imaging of the soft-tissue tumor present in the intermuscular compartment

over the surface of ulna abutting the swelling, but no periosteal reaction was noted. A radiological diagnosis of “soft-tissue mass” was made.

DISCUSSION

Virchow^[6] first described leiomyomas. Stout^[7] reported 13 cases of isolated leiomyomas of limbs and quoted a reference of further 45 cases earlier reported in literature, though none of his cases were diagnosed preoperatively. Kloefer *et al.*^[8] described the hereditary variety which causes multiple leiomyomas. Bulmer^[9] described^[10] patients of deep soft-tissue tumor of extremities seen at the Robert Jones and Agnes Hunt Orthopaedic Hospital during the period of 1952–1963. Billings *et al.*^[10] reported a series of 36 such cases.

Deep leiomyomas are extremely rare and only a few cases have been reported in literature.^[1] Only 60 cases have been reported in English literature so far and such lesions are now accepted as rare neoplasms.^[4] The exact pathogenesis of leiomyomas remains unclear. Goodman and Briggs^[11] stated that these deep leiomyomas arise from smooth muscle rests or undifferentiated mesenchymal cells. The origin of these tumors from vessel walls has been suggested.^[7]

The existence of these lesions was questioned earlier, but now it is considered to be a definitive entity.^[10] These tumors are more common in lower limbs than in upper limbs.^[3,12] Cutaneous leiomyomas arise from arrector pili muscles, whereas vascular type originates from smooth muscles of the vein.^[13]

They are commonly seen in the 3rd–6th decades of life and females are affected twice as compared with males.^[7] Misumi *et al.*^[14] reported these lesions in the age group ranging from 3 to 62 years and 2:1 male preponderance. Solitary leiomyomas of cutaneous and subcutaneous origin do not show any preponderance for race or gender.^[7] Leiomyomas of extremities may be superficial and deep and deep lesions can be vascular or avascular.^[12] Deep non-vascular soft-tissue leiomyomas as in the present case are extremely rare and only few cases have been reported. Furthermore, very few cases of deep soft-tissue leiomyomas with the involvement of bone have been reported in the literature.^[15] Primary leiomyomas of the bone are again very rare and only about 20 cases have been reported so far.^[15] The radiological findings of the lesions on the adjacent surface of the ulna raised the suspicion of this being a bony tumor, but the possibility was ruled out by pre-operative investigations as discussed below. The bone sites reported are mandible, maxilla (tooth socket), and temporal bone. Only a few cases involving the appendicular skeleton which includes neck of femur, tibia, and ulna have been reported.^[16]

Deep soft-tissue leiomyomas of forearm may mimic primary bone tumor as in the present case and the bone involvement raises further other possibilities.^[15] Variations in the size of these tumors have been recorded in vascular type leiomyomas, particularly during pregnancy, but no such history was available

in the present case.^[17] These tumors may be confused with myositis ossificans as some isolated deep soft-tissue leiomyomas may show scattered calcifications.^[11] Myositis ossificans remains one of the differential diagnoses and the presence of scattered calcifications may further confuse the diagnosis, but no such calcifications were seen in this case, so the possibility of myositis ossificans was ruled out.^[11] These tumors are often found on extensor surface and are slow growing, and pain may bring these to the fore. All these features were noticed in the presenting case also. The pain could be because of compression of cutaneous nerves or contraction of smooth muscles.^[7] Leiomyomas may attain significant size, particularly in deeper soft-tissue compartment as found in the present case. The size of present tumor was 8 cm × 5 cm × 2.5 cm, whereas leiomyomas of upper extremities of the size of 30 cm × 29 cm × 12 cm have also been reported.^[18] The differential diagnosis includes bony tumor, leiomyosarcoma, lipoma, schwannoma, neurofibroma, tumor of tendon sheath, and hemangioma.^[15]

There are no specific radiological features of deep soft-tissue leiomyomas and these may resemble any other soft-tissue tumor. The radiological differential diagnosis includes lipoma, leiomyosarcoma, schwannoma or neurofibroma, hemangioma, and giant cell tumor of tendon sheath. The absence of periosteal reaction, defined margins, and no extension into adjacent soft tissue along with non-involvement of metaphysis or diaphysis ruled out the possibility of tumor arising from bone in the present case. Moreover, the center of lesion was more so in the intermuscular compartment as compared with the tumors arising from bone where it is intraosseous.

Irrespective of the site of their presentation, these tumors have strict diagnostic criteria. Atypia and mitotic activity are absent to minimal and seen in <1 of 50/high-powered field as was seen in the present case.^[10] The core biopsy of the lesion was taken which showed tumor arranged in the form of short interlacing fascicles. Tumor cells were mildly pleomorphic with oval- to spindle-shaped nuclei, coarse chromatin, conspicuous nucleoli, and abundant amount of cytoplasm. Tumor cells contained elongated nuclei with moderate amount of eosinophilic cytoplasm. Malignant transformation in the leiomyomas of the

finger and forearm has also been described.^[19,20] These tumors should be approached with precautions and only wide excision should be done until histopathological diagnosis confirms the absence of nuclear atypia, necrosis, and mitotic activity to rule out the possibility of malignancy. There were no necrosis and nuclear atypia, though infrequent mitosis was reported. In view of these findings, possibility of malignancy was ruled out. On IHC of core biopsy, the tumor cells showed strong cytoplasmic positivity for smooth muscle actin immunostain. The S-100 immunostain [Figure 3] was non-contributory, thereby suggesting the tumor to be a leiomyoma and benign in nature. Even the histopathological reporting revealed only focal nuclear positivity for S-100. Overall features were consistent with leiomyoma. Estrogen receptors, Bcl2, CD99, and CD34, are also evaluated in such cases, but receptor status was not done in the present case, as somatic leiomyomas are not usually positive for hormonal receptors.^[10] Total excision of the tumor was done, which was firm to hard in consistency, spherical, grayish-yellow circumscribed mass of size 12 cm × 7 cm [Figure 4] imbedded in the deeper layers of the forearm extensor muscles and abutting ulna [Figure 5]. The lesion was non-encapsulated. The diagnosis was confirmed on histopathology and IHC as discussed earlier.

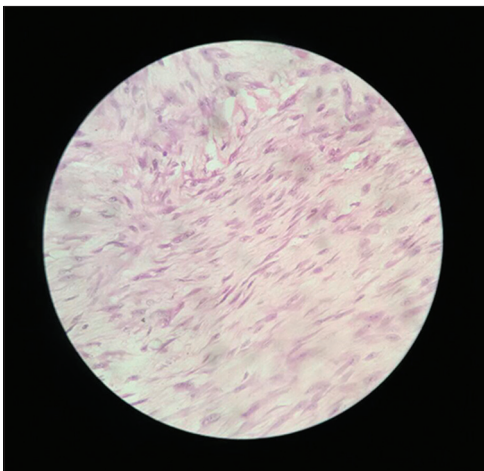


Figure 3: Immunohistochemistry of the tumor

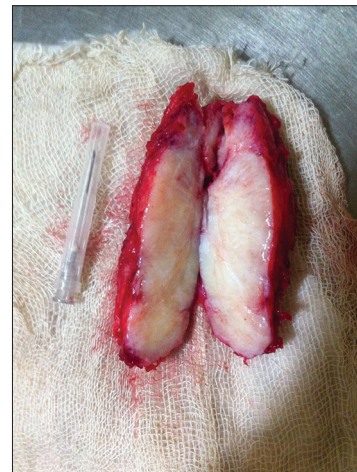

Figure 4: Specimen of the excised tumor

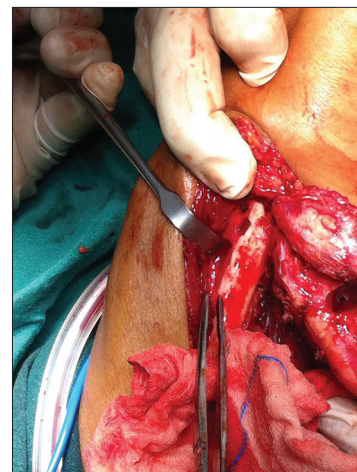

Figure 5: Tumor occupying the deeper layers of the extensor muscles of the forearm

The definitive treatment of these lesions is total, wide excision as it cures and pathological diagnosis can also be confirmed. No recurrence has been reported in such cases during the mean follow-up of 58.7 months.^[10] This swelling was excised in toto. It was adherent with the surrounding muscles at places and had moderately defined facial planes. Parts of muscles adherent with the swelling were also excised along with the tumor. The eroded surface of the ulna was curetted. The wound was drained and closed in layers. Post-operative period was uneventful. The histopathological examination of lesion revealed leiomyoma without any evidence of malignancy and IHC was also confirmatory of leiomyoma.

CONCLUSION

The case is presented here for its extreme rarity and very high chances of possibility of misdiagnosis. Deep non-vascular soft-tissue leiomyoma in the forearm, though is extremely rare, should be considered for the differential diagnosis of any single/solitary slow-growing firm mass of the extremity. Adequate excision of the lesion along with excision of surrounding muscles must be done and be proved by histopathology and IHC, as was followed in the present case. Malignant transformation in these tumors is very rare and so is the recurrence.^[21] Long-term prognosis of these cases has not been reported.^[15] Although the tumor was completely excised, masterly inactivity in the form of clinicoradiological follow-up is recommended to the patients.

REFERENCES

- Bommireddy B, Gurram V. Deep soft tissue leiomyoma of forearm: A case report and review of literature. *J Clin Diagn Res* 2016;10:RD03-5.
- Robbins SL, Cotran RS, Kumar V. *Pathologic Basis of Disease*. 3rd ed. Philadelphia, PA: WB Saunders Co.; 1984. p. 1136-7.
- Robinson SC, Kalish RJ. Leiomyoma in the hand. A case report. *Clin Orthop Relat Res* 1990;255:121-3.
- Fitzhugh VA, Wenokor C, Beebe KS, Aisner SC. Leiomyoma of deep soft tissue mimicking calcific myonecrosis. *Radiol Case Rep* 2016;11:430-3.
- Neviaser RJ, Adams JP. Vascular lesions in the hand. Current management. *Clin Orthop Relat Res* 1974;100:111-9.
- Virchow R. Ueber makroglossie und pathologische neubildung quergestreifter muskelfasern. *Arch Pathol Anat Physiol Klin Med* 1854;7:126-38.
- Stout AP. Solitary cutaneous and subcutaneous leiomyoma. *Am J Cancer* 1937;29:435-69.
- Kloepfer HW, Krafchuk J, Derbes V, Burks J. Hereditary multiple leiomyoma of the skin. *Am J Hum Genet* 1958;10:48-52.
- Bulmer JH. Smooth muscle tumours of the limbs. *J Bone Joint Surg* 1967;49B:52-8.
- Billings SD, Folpe AL, Weiss SW. Do leiomyomas of deep soft tissue exist? An analysis of highly differentiated smooth muscle tumors of deep soft tissue supporting two distinct subtypes. *Am J Surg Pathol* 2001;25:1134-42.
- Goodman AH, Briggs RC. Deep leiomyoma of an extremity. *J Bone Joint Surg* 1965;47:529-32.
- Arenas AJ, Uribiola E, Pampliega T, Cordoba A. Deep intramuscular leiomyoma of the lower limb. *Acta Orthop Belg* 1993;59:211-3.
- Hirata H, Kusuzaki K, Fukutome K, Maeda M, Uchida A. A hand mass that became painful 13 years after onset. *Clin Orthop Relat Res* 2005;433:265-70.
- Misumi S, Irie T, Fukuda K, Tada S, Hosomura Y. A case of deep soft tissue leiomyoma: CT and MRI findings. *Radiat Med* 2000;18:253-56.
- Ramachandran R, Rangaswami R, Raja DK, Shanmugasundaram G. Deep soft-tissue leiomyoma of the forearm mimicking a primary bone tumour of the ulna. *Radiol Case Rep* 2014;9:960.
- Aisner SC, Blacksin M, Patterson F, Hameed MR. A painful tibial mass in a 37-year-old man. *Clin Orthop Relat Res* 2008;466:756-9.
- Smith JW, Danon A, Padgett D, Johanson L. Leiomyomas of the lower extremity. *Orthopedics* 1991;14:594-7.
- Drew EJ. Large leiomyoma of the upper extremity. *Am J Surg* 1966;112:938-40.
- Kilpatrick SE, Mentzel T, Fletcher CD. Leiomyoma of deep soft tissue. Clinicopathologic analysis of a series. *Am J Surg Pathol* 1994;18:576-82.
- Yagi K, Hamada Y, Yasui N. A leiomyoma arising from the deep palmar arterial arch. *J Hand Surg Br* 2006;31:680-2.
- Ledesma-Medina J, Oh KS, Girdany BR. Calcification in childhood leiomyoma. *Radiology* 1980;135:339-41.